

## Laser-assisted hair removal: Side effects of Q-switched Nd:YAG, long-pulsed ruby, and alexandrite lasers

Christopher A. Nanni, MD, and Tina S. Alster, MD *Washington, DC*

**Background:** Laser-assisted hair removal has become popularized using wavelengths in both the red and infrared regions of the electromagnetic spectrum. These photoepilation devices target follicular melanin or an exogenous pigment placed within the follicle resulting in thermal damage to the hair follicle and shaft. However, melanocytes and keratinocytes located within the superficial layers of the skin also absorb red and infrared laser radiation. This may result in unwanted epidermal injury during the hair removal process.

**Objective:** The purpose of this study was to examine a large patient population to determine the frequency of side effects using 3 different hair removal laser systems with various wavelengths, pulse durations, and treatment protocols.

**Methods:** A retrospective chart review and digital photographic analysis of the side effects resulting from 900 consecutive laser-assisted hair removal treatments delivered over a 24-month study period, by means of either a Q-switched Nd:YAG laser with pretreatment wax-epilation and topical carbon solution, a long-pulse ruby laser with a contact cooling tip, or a long-pulse alexandrite laser are reported.

**Results:** Treatment pain, erythema, edema, hypopigmentation and hyperpigmentation, blistering, crusting, erosions, purpura, and folliculitis were observed. The majority of undesirable tissue effects occurred on tanned skin or in Fitzpatrick skin phototypes III and higher. The ruby and alexandrite laser systems resulted in the majority of side effects seen. The effects of seasonal variations, anatomic treatment location, and sun exposure were striking within the ruby and alexandrite laser groups. No infections, scarring, or long-term complications occurred.

**Conclusion:** Laser-assisted hair removal is a safe procedure when patient characteristics such as skin type, anatomic location, and sun-exposed or tanned skin are considered during selection of laser treatment parameters. Lasers emitting wavelengths with high melanin absorption capabilities should be used in a conservative manner when treating patients with dark skin phototypes or suntans. No long-term complications, infections, or scarring occurred in this study population. (*J Am Acad Dermatol* 1999;41:165-71.)

The science and technology of laser-assisted hair removal has grown rapidly since the introduction of the first Food and Drug Administration–approved hair removal laser system in 1996. Currently, several lasers and light sources are available and marketed for the treatment of unwanted or excessive hair. Many of these systems claim to be safe and effective for a wide variety of

skin types and anatomic locations. Lasers with wavelengths in the red and infrared portion of the electromagnetic spectrum are most often used for hair removal because they effectively target melanin in the hair follicle and can potentially penetrate to the appropriate depth of the dermis. To target the follicle, these lasers either rely on endogenous melanin within the follicular epithelium and hair shaft, or on the placement of an exogenous carbon solution that can be targeted in the hair follicle.

Whereas the goal of laser-assisted hair removal is permanent follicular damage, there is also a risk of epidermal injury during the hair removal process. Any melanin-containing structure, such as a melanocyte, keratinocyte, or nevus, may also sustain ther-

From the Washington Institute of Dermatologic Laser Surgery.  
Accepted for publication March 5, 1999.  
Reprint requests: Tina S. Alster, MD, 2311 M Street, N.W. Suite 200,  
Washington, DC 20037.  
Copyright © 1999 by the American Academy of Dermatology, Inc.  
0190-9622/99/\$8.00 + 0 16/1/98497

**Table I.** Number and type of laser treatments stratified by anatomic location

Anatomic location	Nd:YAG (SoftLight)	Ruby (EpiLaser)	Alexandrite (LPIR)	Total
Face	91	80	81	252
Neck	12	7	12	31
Torso	64	38	54	156
Arms	32	8	10	50
Axillae	40	28	27	95
Inguinal region	56	48	42	146
Legs	69	42	59	170
Total	364	251	285	900

**Table II.** Laser treatment parameters

Skin type	Nd:YAG		Ruby		Alexandrite	
	No.	Mean fluence (range)	No.	Mean fluence (range)	No.	Mean fluence (range)
I	52	3.39 (3-4)	48	22.85 (17-25)	50	23.9 (18-25)
II	127	3.26 (2-4)	108	21.5 (15-25)	111	22.7 (15-25)
III	103	3.01 (2-4)	51	16.2 (12-20)	82	17.5 (12-20)
IV	44	2.59 (2-3)	29	12.8 (10-14)	24	13.4 (10-15)
V	38	2.37 (2-3)	15	10.5 (10-12)	18	10.8 (10-12)
Total	364	3.03 (2-4)	251	19.02 (10-25)	285	19.88 (10-25)

**Table III.** Side effect rates

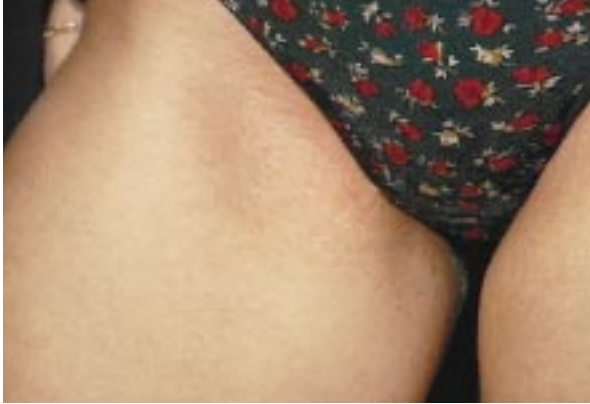Side effect	Q-switched Nd:YAG (n = 364)	Long-pulsed ruby (n = 251)	Long-pulsed alexandrite (n = 285)	Overall occurrence
Transient erythema	100%	94%	96%	97%
Perifollicular edema	100%	95%	95%	97%
Treatment pain	87%	76%	79%	81%
Folliculitis	35%	< 1%	< 1%	14%
Hyperpigmentation	3%	11%	19%	10%
Hypopigmentation	< 1%	18%	17%	10%
Crusting	< 1%	12%	12%	9%
Purpura	18%	3%	3%	7%
Erosions	< 1%	2%	2%	1%
Scarring	0	0	0	0

mal injury when irradiated by red and infrared lasers. Although hair shafts are often darker in color than the surrounding skin, partial absorption of applied laser energy may occur by epidermal chromophores. Methods to protect the epidermis during laser-assisted hair removal have included contact cooling laser tips and topical application of cooling gels and cryogenes. Epidermal cooling thus serves to reduce the amount of superficial thermal damage sustained upon laser impact. In addition, the preoperative use of topical skin lighteners such as hydroquinone, tretinoin, azelaic acid, and kojic acid to decrease epidermal melanin could also provide a protective effect during laser irradiation.

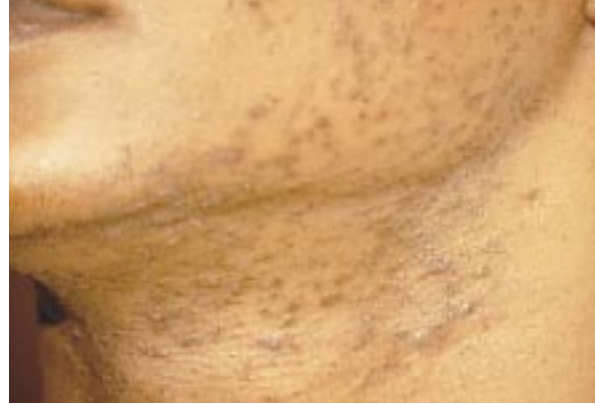Despite all efforts to protect the epidermis from damage, photoepilation may result in clinically significant adverse reactions. The present retrospective study examines the side effects of 900 consecutive laser-assisted hair removal treatments by means of either a Q-switched (QS) Nd:YAG, long-pulsed ruby, or long-pulsed alexandrite laser.

## MATERIAL AND METHODS

A retrospective chart review of 900 consecutive laser-assisted hair removal treatments was conducted over a 24-month time period. A total of 156 patients (27 male, 129 female, age range, 18-74 years) with 300 anatomic areas involved were included in the analysis. Areas of unwanted



**Fig 1.** Erythema and mild perifollicular edema immediately after laser-assisted hair removal occurred in virtually all patients undergoing the procedure.



**Fig 2.** Exacerbation of folliculitis after SoftLight laser process (waxing, topical carbon-based solution application, low fluence Q-switched Nd:YAG laser irradiation).

hair growth on the face, torso, and extremities were treated. Skin phototypes I-V were represented. No specific preoperative skin care regimen nor topical anesthesia was used. Hair removal treatments by means of either a QS Nd:YAG, long-pulsed ruby, or long-pulsed alexandrite laser were performed. The choice of laser system used was based on each laser's availability and working condition and randomly assigned rather than on distinct patient selection criteria (Table I). In general, patients with lighter skin tones were treated with higher fluences than those with darker skin tones (Table II). All laser treatments were delivered on a monthly basis.

The QS Nd:YAG laser system (SoftLight, Thermolase Corporation, La Jolla, Calif) was used at a 1064 nm wavelength and 50 ns pulse duration. Fluences ranging from 2 to 4 J/cm<sup>2</sup> (average, 3 J/cm<sup>2</sup>) were delivered through a 7-mm spot size at 9 Hz. The SoftLight hair removal process involved wax epilation of hair-bearing areas with subsequent topical application of a patented carbon solution. After its massage into the skin, excess surface carbon was manually removed. Laser energy was then applied to the area by means of 10% to 20% pulse overlap until the black carbon residue was fully vaporized from the cutaneous surface.

The long-pulse ruby system (EpiLaser, Palomar Medical Technologies, Beverly, Mass) at 694 nm and 3 ms pulse duration was used at fluences ranging from 10 to 25 J/cm<sup>2</sup> (average, 19 J/cm<sup>2</sup>) with a 10-mm spot and repetition rate of 0.5 Hz. Laser spots were placed in an adjacent, nonoverlapping pattern. The EpiLaser procedure required shaving of excess hair before delivery of laser energy through a sapphire lens cooling tip to reduce the amount of epidermal injury by singed surface hairs.

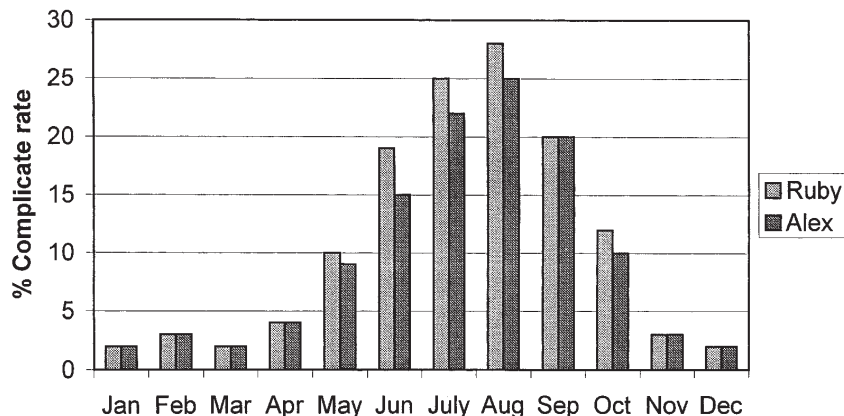
The long-pulse alexandrite laser (LPIR, Cynosure, Chelmsford, Mass) at 755 nm and average 10 ms pulse duration was used to deliver fluences ranging from 10 to 25 J/cm<sup>2</sup> (average, 20 J/cm<sup>2</sup>) through a 10-mm spot size at 1 Hz. Similar to the ruby system process, hair-bearing areas were first shaved before application of a chilled water-based gel (eg, K-Y jelly) and delivery of adjacent, nonoverlapping laser pulses.

Postoperative care for all patients included sun avoidance until erythema and cutaneous irritation had cleared (at least 2 to 3 days). No harsh soaps, scrubs, glycolic or retinoic acid-containing products, topical acne therapy, facial peels, or manipulation of the treatment areas were permitted. Vesiculation and crusting were treated with hydrogen peroxide cleansing with subsequent topical application of hydrophilic petrolatum (Aquaphor, Beiersdorf, Inc, Norwalk, Conn) or polymyxin B sulfate/bacitracin ointment twice daily. Postinflammatory hyperpigmentation was treated with topical application of mid-potency corticosteroid cream (Topicort, Hoechst Marion Roussel, Kansas City, Mo) mixed with equal parts hydroquinone (Solaquin Forte, ICN Pharmaceuticals, Costa Mesa, Calif), and 5% glycolic acid cream (GlyDerm, ICN Pharmaceuticals) on a nightly basis. No patients were prescribed a prophylactic bleaching program. Patients with evidence of hypopigmentation were encouraged to expose the affected skin areas gradually to natural sunlight (15 to 30 minutes) 3 times weekly.

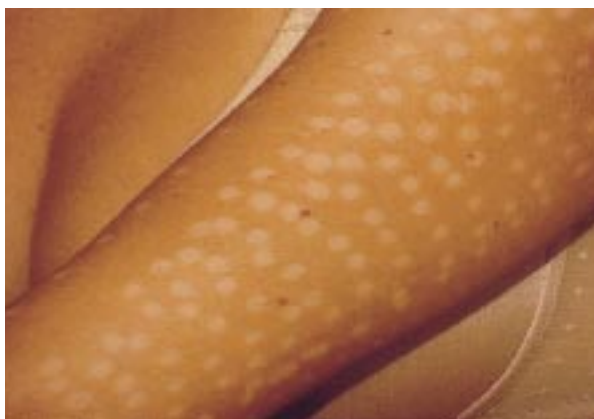## RESULTS

Perifollicular edema and posttreatment erythema were the most common side effects observed within all laser groups (Table III; Fig 1). This acute reaction cleared rapidly, usually within 1 to 4 hours after treatment. Mild and transient treatment pain occurred in upwards of 87% of patients treated with any laser system, with the need for topical or local anesthesia in fewer than 1% of patients.

The QS Nd:YAG laser system resulted in the fewest side effects. Folliculitis occurred in 35% of patients and was most commonly seen on the face, neck, and inguinal regions (Fig 2). Hypopigmentation and hyperpigmentation were rarely seen. Pain during treatment, especially at the nape of the neck, upper lip, sacrum, and areas of redundant or fatty tissue, was commonly experienced.



**Fig 3.** Overall ruby and alexandrite (*Alex*) laser side effect rates by season. Side effects/complications included vesiculation, scab formation, pigmentary alteration.



**Fig 4.** Hypopigmentation noted 1 month after long-pulsed ruby laser treatment of hypertrichosis.

The long-pulse ruby and alexandrite laser systems produced equivalent and an increased number of side effects that were influenced by skin type (Table IV), seasonal variations (Fig 3), and patient history of recent sun exposure. Complication rates also varied according to the anatomic location treated (Table V). The extremities were most commonly affected, and sun-protected areas such as the axillary and inguinal regions resulted in the fewest treatment side effects. Blistering and fine epidermal crusting as well as hypopigmentation and purpura were experienced more commonly in darker skin tones (phototypes III and higher) or in tanned skin (Figs 4 and 5). Average duration of postinflammatory hyperpigmentation was 2 months, whereas hypopigmentation typically persisted for 3.5 months. Long-term adverse sequelae and scarring were not observed with any of the laser systems under study.

**Table IV.** Overall side effect rates stratified by skin phototype

Skin phototype	Side effect rate		
	Nd:YAG (n = 364)	Ruby (n = 251)	Alexandrite (n = 285)
I	2%	< 1%	< 1%
II	2.7%	3.2%	3.2%
III	8.5%	9.4%	9.3%
IV	10.0%	18.7%	18.2%
V	25.2%	37.8%	37.7%

## DISCUSSION

The technology of laser-assisted hair removal is advancing rapidly, making it difficult for even the most experienced laser surgeon to keep abreast with the latest devices being marketed for photoepilation. The number of lasers and light sources currently available for hair removal and their various treatment protocols have created much confusion. Excessive claims from laser companies and laser operators regarding hair removal safety in all skin types have also misled the novice laser surgeon to develop a dangerously lax attitude toward the operation of these devices, even permitting their use by nonmedical staff. The fact is that all photoepilation systems, whether high-intensity light sources or lasers, target follicular melanin. Therefore all hair removal devices provide a significant opportunity for epidermal and dermal injury during the epilation process. No pre-programmed computers or laser company-supplied guidelines are sufficient to prevent side effects. Therefore it is essential that the laser operator be well educated as to the potential risks of

**Table V.** Overall side effect rates stratified by anatomic location

Location	Side effect rate
Extensor extremities	22%
Chin and anterior neck	13%
Shoulders	10%
Abdomen	10%
Inguinal region	5%

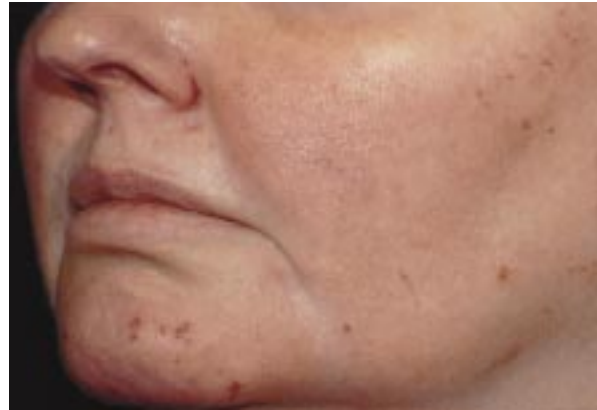photoepilation and have a thorough understanding of laser-tissue interaction before embarking upon the laser-assisted hair removal process.

The side effects of laser-assisted hair removal are not always trivial, particularly if left untreated. The most important factors affecting negative outcomes from laser-assisted hair removal relate to melanin and melanocyte activation (eg, dark skin type, tanned skin, chronically sun-exposed body areas such as the forearms and face) and to the use of excessively high energy densities.<sup>1,2</sup> Clearly, laser wavelength is another key factor influencing treatment efficacy and complication rates because different lasers produce unique side effects based on specific absorption properties.<sup>3-5</sup> In general, the shorter the wavelength, the more the laser energy will be absorbed by melanin and may potentially result in epidermal damage.<sup>6-9</sup>

Laser pulse duration can also affect potential side effects. The longer the pulse duration, the less likely smaller structures in the epidermis (eg, melanosomes) will be injured and the more likely larger pigmented structures (eg, pigmented follicles) will be thoroughly heated.<sup>10-14</sup> Short (eg, nanosecond) pulse durations typically lead to destruction of smaller pigmented cutaneous structures and, thus, effect the removal of epidermal and dermal pigmented lesions (eg, lentigines, nevi of Ota).<sup>15-23</sup>

Treatment discomfort, postoperative erythema, and perifollicular edema are considered side effects of laser surgery, but are actually expected during the laser hair removal process. These signs are clinical end points that guide the laser operator and, in moderation, indicate effective treatment.

The Nd:YAG laser at a 1064 nm wavelength is ideal for treating patients with darker skin tones.<sup>1,24-27</sup> The relatively long infrared wavelength has less affinity for melanin than the red light ruby and alexandrite systems. Most of the side effects that occurred with the Nd:YAG hair removal laser process were mild (eg, swelling, folliculitis, discomfort) and probably related to pretreatment wax epilation rather than to the laser treatment itself. Treatment pain occurred when maximal laser repetition rates were



**Fig 5.** Crusting 4 days after long-pulsed alexandrite laser irradiation of terminal facial hairs.

used and when treatment was administered over areas of loose skin such as the nape of the neck and sacrum. Blister formation and pigmentary changes were rarely observed even when treating a wide range of skin types. Despite its favorable side effect/complication profile, the Nd:YAG laser does not typically effect long-term hair removal because of its Q-switched nature (eg, the pulse is too short to adequately heat the targeted follicle) and because of the use of low fluences involved in the patented process.<sup>12</sup>

On the other hand, the long-pulsed 694-nm ruby light is not only avidly absorbed by melanin in the hair shaft and follicle, but its longer pulse duration results in selective and effective thermal damage to the follicle.<sup>10,28,29</sup> To protect melanin-containing epidermal structures, a "cooling handpiece" is concomitantly applied to the skin during treatment, effectively decreasing surface skin temperature and preventing unwanted thermal injury to epidermal pigment. Intermittent placement of the sapphire tip on the skin thus adequately cools the epidermis, but not the deeper dermis where the hair papilla resides, allowing deeper follicular structures to be damaged.

Treatment pain may occur when using high fluences of the ruby system or when treating sensitive body areas such as the inguinal region or upper lip; however, it is often milder than that experienced with QS Nd:YAG and alexandrite laser irradiation. This is most likely because of the analgesic properties of the contact cooling tip. Thus topical or intralesional anesthesia is rarely necessary during EpiLaser treatment. Vesiculation, crusting, and hyperpigmentation may occur in dark skin types or tanned skin, and purpura can also be seen when laser pulses have been overlapped or in areas where adequate pressure with the cooling tip is difficult to apply.



The long-pulsed (5 to 20 ms) alexandrite laser system at 755 nm affects follicular melanin in much the same manner as does the long-pulsed ruby system, but with potentially less risk of unwanted hypopigmentation because of its slightly reduced absorption by melanin.<sup>12,13,15,20</sup> In addition, the topical cooling gel used concomitantly with laser irradiation provides a "heat sink" and thereby decreases the risk of epidermal injury. Although the present study did not delineate the side effects according to the different pulse durations used (5, 10, and 20 ms), the 20-ms pulse duration would be expected to produce fewer epidermal side effects because of its relative sparing of small melanin-containing cells in the epidermis.<sup>12</sup> In fact, this epidermal-sparing effect at longer pulse widths was observed anecdotally with a decrease in postinflammatory hyperpigmentation within treatment areas using the 20-ms pulse width option.

With long-pulse alexandrite laser irradiation, treatment pain was experienced with the use of high fluences or during treatment of sensitive body areas. Vesiculation, crusting, and hyperpigmentation occurred more often in dark skin phototypes and in tanned skin. The incidence of these complications would be expected to be minimized by using lower energy densities and by avoiding treatment of tanned skin.

The increased number of complications observed during the spring and summer months was most likely due to increased sun exposure and tanning during these seasons. Similarly, variability in complication rates among different anatomic areas may also be attributed in part to sun exposure. The extensor forearms, face, and upper back are areas commonly exposed directly to solar radiation and have higher intrinsic melanin content.

A particularly interesting finding from this study was the absence of any reported cutaneous infections. Herpes simplex virus (HSV) infections after treatment of the perioral region might be an expected complication of laser treatment based on the fact that HSV reactivations are readily induced by trauma. However, no patients (even those with history of HSV) reported HSV infection after laser-assisted hair removal despite the lack of any antiherpetic prophylaxis.<sup>30,31</sup> Therefore, unless a patient has a strong history of perioral HSV reactivation, we do not recommend the routine administration of preoperative oral antiviral medications during laser-assisted hair removal, even when using high fluences in the perioral region.

Even when proper patient selection and treatment parameters are followed, laser-assisted hair

removal may result in unwanted cutaneous side effects. Thus the process should be given the respect typically shown to other laser procedures. It is important to realize that side effects and efficacy of hair removal are both dose-related. Thus, whereas the use of higher fluences will effect increased hair removal, there is a greater incidence of unwanted side effects. Fortunately, the majority of photoepilation side effects are mild and transient and, when proper postoperative care is administered, permanent complications may be easily avoided.

This comprehensive review of laser-assisted hair removal examined a large number of treatment cases and revealed that photoepilation may be performed safely if close attention is paid to skin phototype, patient sun exposure, and anatomic location being treated. In general, the 3 laser systems reported herein had similar side effect profiles using the laser techniques and treatment protocols outlined. Long-pulsed ruby and alexandrite laser irradiation had higher rates of postoperative pigmentary alteration, whereas purpura formation and folliculitis were more common with the QS Nd:YAG laser; the latter presumably because of the concomitant waxing process. The use of pretreatment skin lighteners in patients with darker skin tones or tans may potentially help to reduce the incidence of postoperative pigmentary changes encountered with these hair removal laser systems.

#### REFERENCES

1. Nanni CA, Alster TS. A practical review of laser-assisted hair removal using the Q-switched Nd:YAG, long-pulsed ruby, and long-pulsed alexandrite lasers. *Dermatol Surg* 1998;24:1399-405.
2. Chernoff WG. Selective photothermolysis for hair removal. *Int J Aesthet Restor Surg* 1997;5:50-4.
3. Anderson RR, Parrish JA. Selective photothermolysis: precise microsurgery by selective absorption of pulsed radiation. *Science* 1983;220:524-7.
4. Anderson RR, Margolis RJ, Watanabe S, et al. Selective photothermolysis of cutaneous pigmentation by Q-switched Nd:YAG laser pulses at 1064, 532, and 355 nm. *J Invest Dermatol* 1989;93:28-32.
5. Polla LL, Margolis RJ, Dover JS. Melanosomes are a primary target of Q-switched ruby laser irradiation in guinea pig skin. *J Invest Dermatol* 1987;77:13-9.
6. Margolis R, Dover J, Polla L, et al. Visible action spectrum for melanin-specific selective photothermolysis. *Lasers Surg Med* 1989;9:389-97.
7. Murphy GF, Shepard RS, Paul BJ, et al. Organelle-specific injury to melanin-containing cells in human skin by pulsed laser irradiation. *Lab Invest* 1983;49:680-5.
8. Watanabe S, Anderson R, Brorson S, et al. Comparative studies of femtosecond to microsecond laser pulses on selective pigmented cell injury in skin. *Phototest Photobiol* 1991;757-62.
9. Sherwood KA, Murray S, Kurban AK, Tan OT. Effect of wavelength on cutaneous pigment using pulsed irradiation. *J Invest Dermatol* 1989;92:717-20.
10. Grossman MC, Dierickx C, Farinelli W, et al. Damage to hair folli-

- cles by normal-mode ruby pulses. *J Am Acad Dermatol* 1996;35:889-94.
11. Lask G, Elman M, Slatkine M, et al. Laser-assisted hair removal by selective photothermolysis: preliminary results. *Dermatol Surg* 1997;23:737-9.
  12. Nanni CA, Alster TS. Long-pulsed alexandrite laser-assisted hair removal at 5, 10, and 20 millisecond pulse durations. *Lasers Surg Med* 1999;24:332-7.
  13. Finkel B, Eliezri YD, Waldman A, Slatkine M. Pulsed alexandrite laser technology for noninvasive hair removal. *J Clin Laser Med Surg* 1997;15:225-9.
  14. Gold MH, Bell MW, Foster TD, et al. Long-term epilation using the EpiLight broad band, intense pulsed light hair removal system. *Dermatol Surg* 1997;23:909-13.
  15. Alster TS, Williams CM. Treatment of nevus of Ota by the Q-switched alexandrite laser. *Dermatol Surg* 1995;21:592-6.
  16. Goldberg DJ, Nychay SG. Q-switched ruby laser treatment of nevus of Ota. *J Dermatol Surg Oncol* 1992;18:817-21.
  17. Geronemus RG. Q-switched ruby laser therapy of nevus of Ota. *Arch Dermatol* 1992;128:1618-22.
  18. Lowe NJ, Wieder JM, Burrows P, Chalet M. Nevus of Ota: treatment with high energy fluences of the Q-switched ruby laser. *J Am Acad Dermatol* 1993;29:997-1001.
  19. Taylor CR, Flotte TJ, Gange RW, Anderson RR. Treatment of nevus of Ota by Q-switched ruby laser. *J Am Acad Dermatol* 1994;30:743-51.
  20. Rosenbach A, Williams CM, Alster TS. Comparison of the Q-switched alexandrite (755 nm) and Q-switched Nd:YAG (1064 nm) lasers in the treatment of benign melanocytic nevi. *Dermatol Surg* 1997;23:239-45.
  21. Tse Y, Levine VJ, McClain SA, Ashinoff R. The removal of cutaneous pigmented lesions with the Q-switched ruby laser and the Q-switched neodymium:yttrium-aluminum-garnet laser. *J Dermatol Surg* 1994;20:795-800.
  22. Goldberg DJ. Benign pigmented lesions of the skin: treatment with the Q-switched ruby laser. *J Dermatol Surg Oncol* 1993;19:376-9.
  23. Waldorf HA, Kauvar AN, Geronemus RG. Treatment of small and medium congenital nevi with the Q-switched ruby laser. *Arch Dermatol* 1996;132:301-4.
  24. Goldberg DJ, Littler CM, Wheeland RG. Topical suspension-assisted Q-switched Nd:YAG laser hair removal. *Dermatol Surg* 1997;23:741-5.
  25. Nanni CA, Alster TS. Optimizing treatment parameters for hair removal using a topical carbon-based solution and 1064-nm Q-switched neodymium:YAG laser energy. *Arch Dermatol* 1997;133:1546-9.
  26. Littler CM. Laser hair removal in a patient with hypertrichosis lanuginosa congenita. *Dermatol Surg* 1997;23:705-7.
  27. Wheeland RG. Laser-assisted hair removal. *Dermatol Clin* 1997;15:469-77.
  28. Dierickx CC, Grossman MC, Farinelli WS, Anderson RR. Permanent hair removal by normal-mode ruby laser. *Arch Dermatol* 1998;134:837-42.
  29. Nanni CA, Alster TS. Treatment of Becker's nevus using a 694-nm long-pulsed ruby laser. *Dermatol Surg* 1998;24:1032-4.
  30. Nanni CA, Alster TS. Complications of carbon dioxide laser resurfacing: an evaluation of 500 patients. *Dermatol Surg* 1998;24:315-20.
  31. Alster TS, Nanni CA. Famciclovir prophylaxis of herpes simplex virus reactivation after laser skin resurfacing. *Dermatol Surg* 1999;25:242-6.